

RESEARCH

Open Access



Suprachoroidal spheroidal mesenchymal stem cell implantation in retinitis pigmentosa: clinical results of 6 months follow-up

Berna Özkan^{1*}, Büşra Yılmaz Tuğan², Cansu Hemşinlioğlu³, Gözde Sır Karakuş³, Özlem Şahin⁴ and Ercüment Ovalı³

Abstract

Purpose This prospective clinical case series aimed to evaluate the effect of suprachoroidal implantation of mesenchymal stem cells (MSCs) in the form of spheroids as a stem cell therapy for retinitis pigmentosa (RP) patients with relatively good visual acuity.

Methods Fifteen eyes of 15 patients with RP who received suprachoroidal implantation of MSCs in the form of spheroids were included. Best-corrected visual acuity (BCVA), 10–2 and 30–2 visual field examination and multifocal electroretinography (mfERG) recordings were recorded at baseline, postoperative 1st, 3rd and 6th months during follow-up.

Results Baseline median BCVA of RP patients was 1.30 (1.00–2.00) logMAR. BCVA has improved to 1.00 (0.50–1.30), 0.80 (0.40–1.30) and 0.80 (0.40–1.30) at the postoperative 1st, 3rd and 6th months, respectively. The improvements from baseline to the 3rd and 6th months were statistically significant ($p=0.03$ and $p<0.001$, respectively). In the 30–2 VF test, median MD was significantly improved at the 6th month compared to baseline ($p=0.030$). In the 10–2 VF test, the median MD value was significantly different at the 6th month compared to the baseline ($p=0.043$). The PSD value of the 10–2 VF test was significantly different at the 6th month compared to the 3rd month ($p=0.043$). The amplitudes of P1 waves in $<2^\circ$, 5° – 10° and 10° – 15° rings improved significantly at the postoperative 6th month ($p=0.014$, $p=0.018$ and $p=0.017$, respectively). There was also a statistically significant improvement in implicit times of P1 waves in 10° – 15° ring at the postoperative 6th month ($p=0.004$).

Conclusion Suprachoroidal implantation of MSCs in the form of spheroids as a stem cell therapy for RP patients with relatively good visual acuity has an improving effect on BCVA, VF and mfERG recordings during the 6-month follow-up period. Spheroidal MSCs with enhanced effects may be more successful in preventing apoptosis and improving retinal tissue healing in RP patients.

Keywords Retinitis pigmentosa, Mesenchymal stem cells, Spheroids, Suprachoroidal implantation

*Correspondence:

Berna Özkan
drbernaozkan@gmail.com

¹ Department of Ophthalmology, Acibadem Mehmet Ali Aydınlar University, Istanbul, Turkey

² Department of Ophthalmology, Kocaeli University, Kocaeli, Turkey

³ Acibadem Labcell Cellular Therapy Center, Istanbul, Turkey

⁴ Department of Ophthalmology, Marmara University, Istanbul, Turkey

Introduction

Retinal degenerative disorders are a group of diseases known for the progressive loss of retinal cells. Retinitis pigmentosa (RP) is the most common hereditary retinal disease that comes under the heading of retinal degenerative disorders. Cumulative damage of the retinal cells causes nyctalopia and peripheral visual field loss in RP.



© The Author(s) 2023. **Open Access** This article is licensed under a Creative Commons Attribution 4.0 International License, which permits use, sharing, adaptation, distribution and reproduction in any medium or format, as long as you give appropriate credit to the original author(s) and the source, provide a link to the Creative Commons licence, and indicate if changes were made. The images or other third party material in this article are included in the article's Creative Commons licence, unless indicated otherwise in a credit line to the material. If material is not included in the article's Creative Commons licence and your intended use is not permitted by statutory regulation or exceeds the permitted use, you will need to obtain permission directly from the copyright holder. To view a copy of this licence, visit <http://creativecommons.org/licenses/by/4.0/>. The Creative Commons Public Domain Dedication waiver (<http://creativecommons.org/publicdomain/zero/1.0/>) applies to the data made available in this article, unless otherwise stated in a credit line to the data.

The progression of the disease damages the central photoreceptors in the late phase. The disease does not affect only photoreceptors. The damage in the photoreceptors affects the surrounding cell layers in the retina, retinal pigment epithelium (RPE) and choroid [1, 2].

At present, there is no treatment that cures RP. Gene therapy is the most promising treatment; however, hundreds of genes cause the disease. Mesenchymal stem cell (MSC) treatment has recently been studied as a viable alternative for different retinal diseases [3–9]. MSCs have been shown to have significant paracrine and immunomodulatory properties by secretion of trophic factors stimulating RPE or similar to those produced by RPE [10–19]. Animal studies demonstrated that MSCs are effective in suppressing chronic inflammation, preventing retinal degeneration, rescuing photoreceptors and preventing apoptosis in neurodegenerative and ischemic retinal disorders [20–26].

The current study aims to evaluate the effect of supra-choroidal implantation of MSCs in the form of spheroids as a stem cell therapy of RP on visual acuity, visual field analysis and electrophysiological testing to reveal potential functional and anatomical impacts of the therapy.

Methods

A prospective, non-randomized, phase I/II clinical trial was conducted in patients with RP at the Department of Ophthalmology, Acibadem University, Medical School (ClinicalTrials.gov Identifier: NCT05712148). The study was approved by the ethics committee of Review Board of Cell, Organ and Tissue Transplantation Department of Turkish Ministry of Health (56,733,164/203 E.3858). The study was performed in accordance with the Declaration of Helsinki. Since the central ethics committee requires individual approval, individual consent was obtained.

Patient evaluation

Fifteen patients with clinical and genetic diagnoses of RP were included in the study. Patients underwent ophthalmic examination including best-corrected visual acuity (BCVA), intraocular pressure, anterior segment examination and dilated fundus examination (with topical tropicamide 1% and phenylephrine 2.5%). Each eye underwent spectral-domain OCT scanning with Cirrus 5000 HD-OCT Angioplex (Carl Zeiss Meditec, Dublin, CA, USA), fundus autofluorescence and fundus fluorescein angiography (Heidelberg Engineering, Germany). MD (mean deviation) and PSD (pattern standard deviation) parameters of 10–2 and 30–2 visual field (VF) testing strategies with a Humphrey Field Analyzer model 750I (Carl Zeiss Meditec, Dublin, CA, USA) were obtained. The electrophysiological function was assessed with mfERG evaluation (MonPack 3, Metrovision, France) according to

the International Society for Clinical Electrophysiology of Vision (ISCEV) guidelines [27]. BCVA was converted to the logarithm of the minimal angle of resolution (log-MAR) equivalent.

The patients were excluded from the study, if they had (1) coexisting ocular pathology that may affect visual acuity, visual field and retinal morphology such as glaucoma, uveitis and previous vitreoretinal surgery, (2) coexisting cataract that may affect mfERG, visual field and/or ocular imaging, (3) refractive error that may affect measurements higher than +6.00D and lower than –6.00D, (4) coexisting systemic diseases that may affect visual function such as diabetes, vasculitis, rheumatological diseases and chronic immunosuppressive use, (5) periocular injection of platelet-rich plasma (PRP) and transcorneal electrical stimulation in the previous 6 months and (6) previous ocular surgery.

Electrophysiologic testing

After 30 min of dark adaptation and pupil dilatation with the application of one drop of tropicamide 1% (Tropicamid, Bilim İlaç, Turkey), phenylephrine 2.5% (Mydrin, Alcon) and proparacaine hydrochloride 0.5% (Alcaine, Alcon), ERG jet electrodes were placed. Multifocal electroretinographies were recorded after pupil dilatation. The stimulated retinal area was subtended in an area of 60°×55°; 61 hexagon stimulants were used with alternating black (5 cd/m²) and white (100 cd/m²) stimulants. The concentric rings were analyzed according to International Society for Clinical Electrophysiology of Vision standards [13]. The amplitude and latencies of P1, N1 and N2 components were recorded for every ring. The mean signal amplitudes (MSAs) of multifocal electroretinography (mfERG) in the macula (central 0°–2°) and the peripheral (2°–5°, 5°–10°, 10°–15° and >15°) signal amplitude changes were evaluated separately.

Spheroidal stem cell preparation

First passage umbilical cord-derived mesenchymal stem cell was obtained from Labcell Cellular Laboratory Center (Acibadem Labmed, Acibadem University, Istanbul) which provides GMP (good manufacturing practices) conditions.

Spheroid production

The spheroid production continued in GMP condition. First passage umbilical cord-derived mesenchymal stem cells were used in the production of spheroids. A total of 100,000 mesenchymal stem cells were suspended with 100 µl. Serum-free medium (MSC NutriStem® XF Medium, Sartorius) containing 1% ciprofloxacin (Polipharma). Each well of the low attachment 96-well plate was seeded with 100,000 cells in

100- μ l medium. The cells were incubated at 37 °C for 48 h. At the end of 48 h, all spheroids were collected with a micropipette and transferred into Ringer's lactate solution (Osel/Biofleks) containing 1% HSA (CSL Behring). Spheroids were washed 3 times with Ringer's lactate solution containing 1% HAS (CSL Behring). Fifty spheroids were produced for one patient (50 spheroids containing 5×10^6 cells were produced). Five of 50 spheroids were reserved for quality control analysis. The remaining 45 spheroid membranes were embedded in the matrix.

Matrix production and cell embedding culture

Matrix mixture containing 225- μ l cryoprecipitate + 22.5- μ l calcium (Adeka) + 2.5- μ l transamine (Haver) was added to each well of the 96-well plates. When the matrix became semi-solid, 45 spheroids were embedded in the middle of the matrix and incubated at 37 °C for 45 min. The matrix, which became completely solid after 45 min, was removed with the help of a scalpel, transferred into Ringer's lactate solution (Osel/Biofleks) containing 1% HAS (CSL Behring) and transferred to the operating room in this solution (Fig. 1).

Quality control analysis

Microbiological blood culture, fungal, endotoxin analysis and purity (ciprofloxacin < 0.1 μ g/ml), efficiency (adipocyte and cartilage differentiation analysis) cell count/viability and flow cytometric analysis (CD34 < %2, CD45 < %4, CD90 > %80, HLA-DR < %4, CD105 > %60 and CD73 > %70) were studied from the reserved spheroids for quality control analyses.

Surgical technique

Patients underwent surgery under general anesthesia. The inferotemporal quadrant was chosen as the surgical area, and a 6.0 Silk was used as the anchoring suture near the limbus conjunctiva, and tenon was opened as 6-mm long cut at 6 mm from limbus parallel to the limbus and the edges of the cut were advanced 3 mm posteriorly. Two 8.0 Vicryl sutures were used as traction sutures at the anterior corners of the conjunctiva. The tenon was dissected over the sclera posteriorly. Then, we performed a 7 \times 7 scleral flap. Anterior margin of the scleral flap was created at 8 mm from the limbus, parallel to the limbus with 30 degrees ophthalmic knife. Two other half-thickness side cuts were made to create a U-shaped flap that has its base parallel to the lateral rectus muscle. Then starting from the inferoanterior edge, a deep scleral flap was dissected with a crescent blade. During the dissection, black choroidal reflex should be observed all around the surface of the flap bed (Fig. 2A). The fibrin plug carrying spheroidal stem cells was placed over the choroid that was seen under the thin sclera (Fig. 2B and C). It was covered by the scleral flap, and the flap was sutured to its original position from its edges with a 7.0 Vicryl suture (Fig. 2D). Tenon and conjunctiva were closed separately with an 8.0 Vicryl suture.

Statistical analysis

IBM SPSS for Windows version 20.0 (SPSS, Chicago, IL, USA) was used to perform all statistical analyses. The assumption of normality was tested with Shapiro–Wilk's test. Continuous variables with normal distribution were presented as mean \pm standard deviation, and continuous variables with no normal distribution were presented as median (25–75th percentile). Counts (percentages)




Fig. 1 **A.** Representative image of spheroids. **B.** Representative image of spheroids embedded in the middle of the matrix transferred into Ringer's lactate solution (Osel/Biofleks) containing 1% HAS (CSL Behring) and transferred to the operating room in this solution

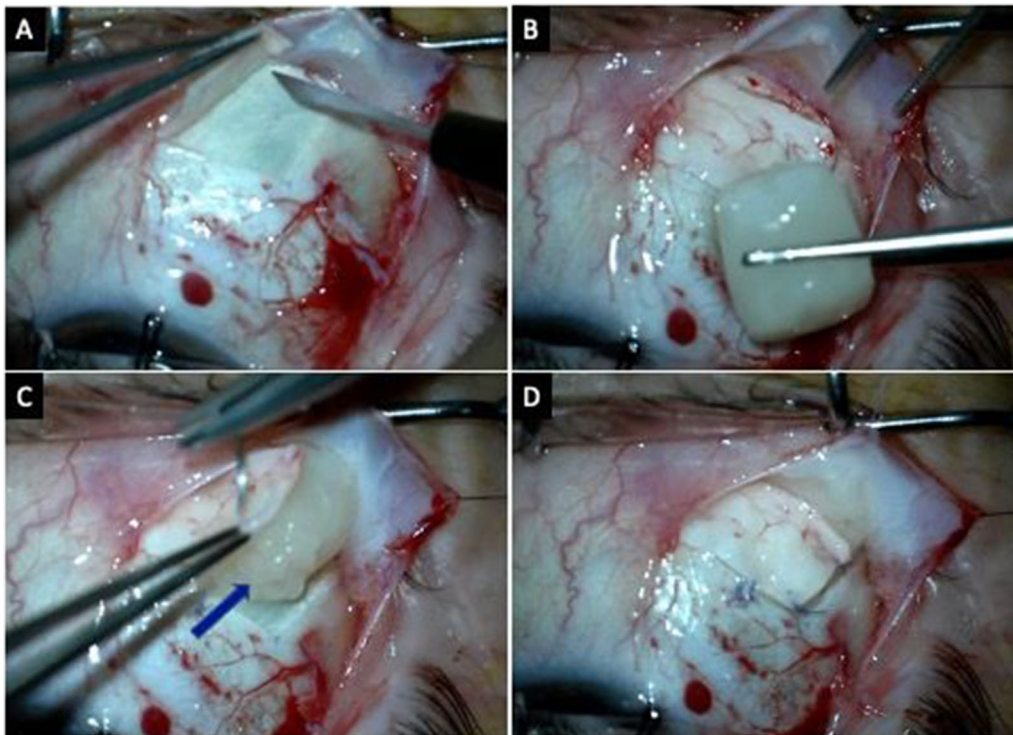


Fig. 2 **a** Preparation of the scleral bed. **b** Matrix containing the spheroids. **c** Matrix placed in the scleral bed. **d** After suturing the flap over the matrix, the sutures are placed tightly in anterior edge of the flap and loosely in the free edge and posterior edge

represented categorical variables. Pre- and post-injection comparisons were analyzed by paired samples t-test/Friedman's two-way ANOVA test, whichever was appropriate. Dunn's test was used for the pairwise multiple comparisons. All statistical analyses were performed with 5% significance, and a two-sided p -value < 0.05 was considered statistically significant.

Results

Fifteen eyes of 15 patients were evaluated in the study. The mean age of the patients was 38.6 ± 12.2 years. Six patients were female, and nine patients were male.

The demographic and clinical features of the 15 study patients are shown in Table 1. The median BCVA (log-MAR) of treated eyes was 1.30 (1.00–2.00) at baseline examination. During the follow-up, BCVA has improved to 1.00 (0.50–1.30), 0.80 (0.40–1.30) and 0.80 (0.40–1.30) at the postoperative 1st, 3rd and 6th months, respectively. The improvements from baseline to the 3rd and 6th months were statistically significant ($p = 0.03$ and $p < 0.001$, respectively). No significant change was observed in BCVA of the fellow eyes at the postoperative 1st, 3rd and 6th months compared to the baseline ($p > 0.05$, for all) (Table 2) (Fig. 3). While no significant difference was found between treated eyes and fellow eyes regarding baseline, month 1, month

3 BCVA values and month 6 BCVA was significantly improved in treated eyes compared to fellow eyes ($p = 0.039$).

The median MD value conducted from treated eyes' 30–2 VF test was 32.18 (30.37–32.82) at baseline. It was 31.5 (29.11–32.59), 31.63 (19.88–32.42) and 30.58 (27.05–32.46) at the 1st, 3rd and 6th month follow-up examinations. The median MD was significantly improved at the 6th month compared to baseline ($p = 0.030$) (Table 2) (Fig. 4). However, there was no difference in the median PSD values of the 30–2 VF test of the treated eyes ($p = 0.218$). The median MD value conducted from treated eyes' 10–2 VF test was 27.69 (25.20–34.33) at baseline. It was 26.29 (21.77–34.26), 26.08 (21.02–34.15) and 28.69 (21.59–34.28) at the 1st, 3rd and 6th months, respectively. The median MD value of the 10–2 VF test of the treated eyes was significantly different at the 6th month compared to the baseline ($p = 0.043$). The mean PSD of the 10–2 VF test of the treated eyes was 5.48 (3.01–6.09), 4.71 (2.98–5.96), 4.76 (1.49–5.34) and 4.95 (1.74–6.25) at baseline, 1st, 3rd and 6th month, respectively. PSD value of the 10–2 VF test of the treated eyes was significantly different at the 6th month compared to the 3rd month (Table 2) (Fig. 5). No significant change was observed in MD and PSD of the both 10–2 and 30–2 VF tests of the fellow eyes ($p > 0.05$, for all) (Table 2).

Table 1 Demographic and visual acuity results according to ETDRS letters and logMAR equivalent of enrolled subjects

No./age (years)/sex/eye	Baseline BCVA (ETDRS letters/logMAR)	1-month BCVA (ETDRS letters/logMAR)	3-month BCVA (ETDRS letters/logMAR)	6-month BCVA (ETDRS letters/logMAR)
1/40/female/right	20/1.3	35/1.0	50/0.7	60/0.5
2/39/male/right	20/1.3	20/1.3	20/1.3	20/1.3
3/24/male/left	35/1.0	60/0.5	65/0.4	65/0.4
4/50/female/right	35/1.0	35/1.0	35/1.0	45/0.8
5/56/male/right	35/1.0	60/0.5	60/0.5	60/0.5
6/10/female/right	35/1.0	45/0.8	45/0.8	45/0.8
7/51/female/left	-/2.0	-/2.0	-/1.7	10/1.5
8/49/female/left	-/3.0	-/2.0	-/1.7	-/1.7
9/32/male/right	65/0.4	70/0.3	75/0.2	75/0.2
10/52/male/left	20/1.30	60/0.5	60/0.5	60/0.5
11/34/female/right	-/2.0	-/2.0	-/2.0	-/2.0
12/34/male/right	-/2.0	20/1.3	20/1.3	20/1.3
13/36/male/right	-/2.0	20/1.3	20/1.3	20/1.3
14/34/male/right	50/0.7	65/0.4	65/0.4	70/0.3
15/35/male/left	50/0.7	60/0.5	65/0.4	75/0.2

BCVA best-corrected visual acuity, ETDRS early treatment for diabetic retinopathy study and logMAR logarithm of minimum angle of resolution

In the mfERG test, the results of 11 patients were analyzed because of poor fixation or artifacts in the test results of the remaining four patients. Table 3 demonstrates the amplitudes of P1 waves of treated and fellow eyes. The amplitudes of P1 waves in <2°, 5°–10° and 10°–15° rings improved significantly at the postoperative 6th month compared to baseline in treated eyes ($p=0.014$, $p=0.018$ and $p=0.017$, respectively) (Fig. 6). Despite the amplitudes of P1 waves in 2°–5° and >15° rings being improved, the changes were not statistically significant. No significant changes were observed in the recordings of the fellow eyes at the 6th month compared to baseline ($p>0.05$, for all). Furthermore, the amplitudes of P1 waves in <2°, 5°–10° and 10°–15° rings were significantly increased in treated eyes compared to fellow eyes at the postoperative 6th month ($p=0.001$, $p=0.009$ and $p=0.027$, respectively).

Implicit times of P1 waves of treated and fellow eyes are depicted in Table 4. There was a statistically significant improvement in implicit times of P1 waves in 10°–15° ring at the postoperative 6th month compared to baseline ($p=0.004$) in treated eyes. The implicit times of P1 waves in <2°, 2°–5°, 5°–10° and >15° rings did not differ after the operation. No significant changes were observed in the recordings of the fellow eyes at the postoperative 6th month compared to baseline ($p>0.05$, for all).

We did not observe any postoperative complications, side effects or adverse effects during the follow-up period.

Discussion

RP is an inherited retinal degeneration that causes progressive visual loss. More than 150 genes were found to be related to the disease, and genetic tests of the patients with similar clinical appearance may still show new unidentified genes [1]. Most of these genes are involved in phototransduction, cell trafficking, outer segment membrane structure, neuronal or immune response, rhodopsin recycling pathways or glucose metabolism [2, 28, 29]. These metabolic pathways play fundamental roles in the function and maintenance of the photoreceptor cells. Change in the photoreceptor metabolism and structure triggers cell death [30]. Additionally, mitochondria of the photoreceptor inner segments are also affected, and they lack antioxidant defense maintained by superoxide dismutase, glutathione dismutase and catalase in patients with RP [31, 32]. The combination of these processes leads to apoptosis, regulated necrosis and autophagy, which result in progressive loss of the photoreceptors and progressive loss of vision.

Mesenchymal stem cells (MSCs) can secrete paracrine factors that affect the neuronal microenvironment. These factors induce proliferation and differentiation in the surrounding cells of the tissue in which they were implanted. They also produce chemo-attractants that stimulate the migration of the cells necessary for tissue healing. The secreted therapeutic factors are composed of growth factors and cytokines, vesicular portion of extracellular micro-vesicles and mitochondria [33]. Growth factors and cytokines cause immune modulation, angiogenesis,

Table 2 BCVA and visual field examination data of retinitis pigmentosa (RP) patients at baseline, 1 month, 3 months and 6 months

		Baseline	Month 1	Month 3	Month 6	p*
BCVA logMAR						
Treated eye	Median (IQR)	1.30 (1.00–2.00) ^a	1.00 (0.50–1.30) ^{ab}	0.80 (0.40–1.30) ^b	0.80 (0.40–1.30) ^b	< 0.001
	Mean ± SD	1.38 ± 0.68	1.02 ± 0.60	0.94 ± 0.56	0.89 ± 0.58	
Fellow eye	Median (IQR)	1.00 (0.70–2.00)	1.30 (0.50–2.00)	1.60 (0.60–2.50)	1.60 (0.70–2.50)	0.152
	Mean ± SD	1.42 ± 0.91	1.38 ± 0.96	1.56 ± 1.02	1.59 ± 1.00	
p		0.888**	0.413***	0.068**	0.039**	
MD 30/2						
Treated eye	Median (IQR)	32.2 (30.4–32.8) ^a	31.5 (29.1–32.6) ^{ab}	31.6 (19.9–32.4) ^{ab}	30.6 (27.1–32.5) ^b	0.029
	Mean ± SD	31.2 ± 3.3	30.8 ± 2.0	31.0 ± 1.9	28.2 ± 8.0	
Fellow eye	Median (IQR)	32.3 (30.3–33.8)	31.9 (30.3–33.6)	32.4 (30.4–33.8)	32.2 (31.3–34.7)	0.985
	Mean ± SD	32.0 ± 2.1	31.9 ± 2.3	32.3 ± 1.9	32.6 ± 1.8	
p		0.829***	0.215**	0.132**	0.051***	
PSD 30/2						
Treated eye	Median (IQR)	3.4 (1.6–5.6)	4.0 (2.1–6.0)	4.8 (2.7–5.6)	4.6 (2.7–5.6)	0.218
	Mean ± SD	3.7 ± 1.8	4.1 ± 1.9	4.1 ± 1.7	4.5 ± 1.9	
Fellow eye	Median (IQR)	3.7 (1.7–6.2)	3.8 (1.5–5.4)	3.5 (1.8–5.6)	3.3 (2.0–4.9)	0.682
	Mean ± SD	3.7 ± 2.2	3.5 ± 2.0	3.8 ± 2.4	3.6 ± 2.0	
p		0.997**	0.465**	0.753**	0.300**	
MD 10/2						
Treated eye	Median (IQR)	27.7 (25.2–34.3) ^a	26.3 (21.8–34.3) ^{ab}	26.1 (21.0–34.2) ^{ab}	28.7 (21.6–34.3) ^b	0.027
	Mean ± SD	28.7 ± 5.0	27.7 ± 5.7	27.5 ± 6.0	28.0 ± 6.6	
Fellow eye	Median (IQR)	30.8 (22.0–32.1)	30.9 (23.8–32.7)	31.6 (27.2–32.9)	30.0 (25.9–31.6)	0.177
	Mean ± SD	28.0 ± 5.0	28.6 ± 5.0	30.3 ± 3.8	29.1 ± 2.6	
p		0.882***	1.000***	0.417***	1.000***	
PSD 10/2						
Treated eye	Median (IQR)	5.5 (3.0–6.1) ^{ab}	4.7 (2.3–6.0) ^{ab}	4.8 (1.5–5.3) ^a	5.0 (1.7–6.3) ^b	0.024
	Mean ± SD	4.8 ± 2.0	4.2 ± 2.0	3.9 ± 2.3	4.3 ± 2.3	
Fellow eye	Median (IQR)	5.7 (4.2–6.1)	5.2 (4.1–6.3)	5.0 (3.5–6.0)	4.9 (3.5–6.7)	0.896
	Mean ± SD	5.1 ± 1.7	5.1 ± 1.7	4.5 ± 1.6	4.7 ± 2.0	
p		0.882***	0.331***	0.470***	0.867***	

BCVA best-corrected visual acuity, MD mean deviation (dB), PSD pattern standard deviation (dB), SD standard deviation and IQR interquartile range

*Friedman’s two-way ANOVA test

**Independent samples t-test

***Mann–Whitney U-test

Medians followed by similar lower case letters are not significantly different

Bold face values represent statistical significance

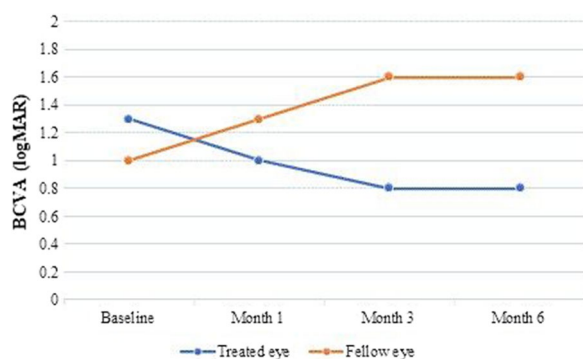


Fig. 3 Trends of BCVA of treated and fellow eyes during the follow-up

anti-apoptosis, anti-oxidation, cell migration and stimulation. The main growth factors and cytokines that mesenchymal stem cells produce are basic fibroblast growth factor, vascular endothelial growth factor, macrophage colony-stimulating factor, placental growth factor, transforming growth factor-beta, insulin-like growth factor-1, interleukin, angiogenin, ciliary neurotrophic factor, brain-derived growth factor and glial cell-derived growth factor [34]. Micro-vesicles contain bioactive molecules, RNA, microRNA, lipids and proteins for intercellular communication, and they regulate the metabolism of the retinal cells [35]. Finally, mitochondria affect the healing

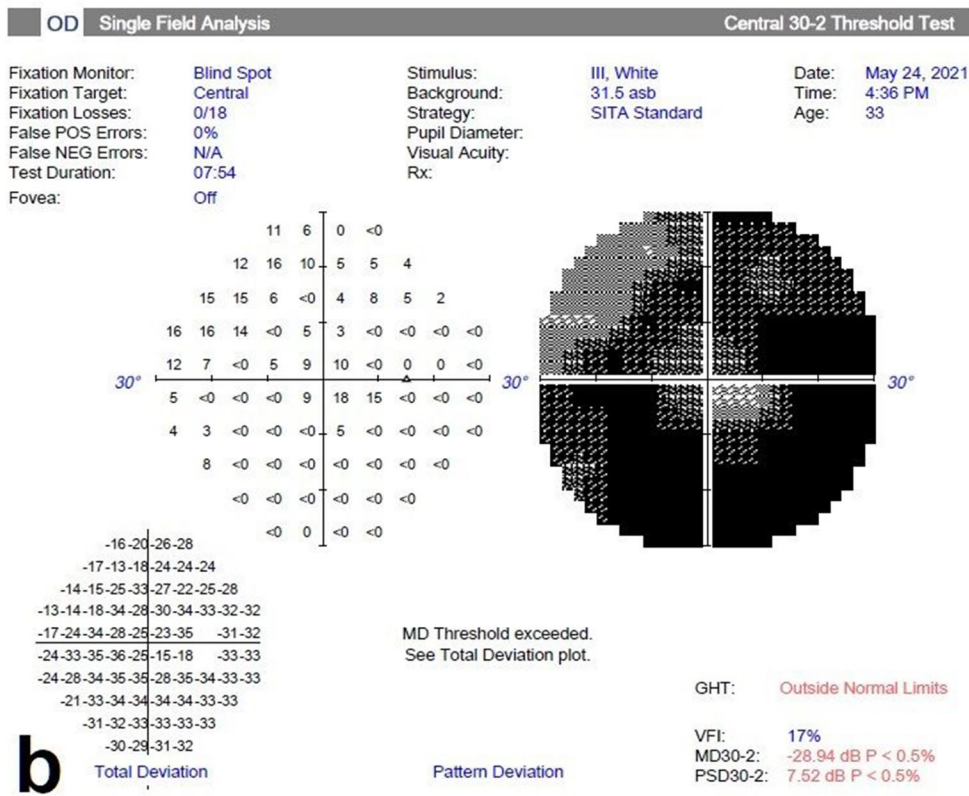
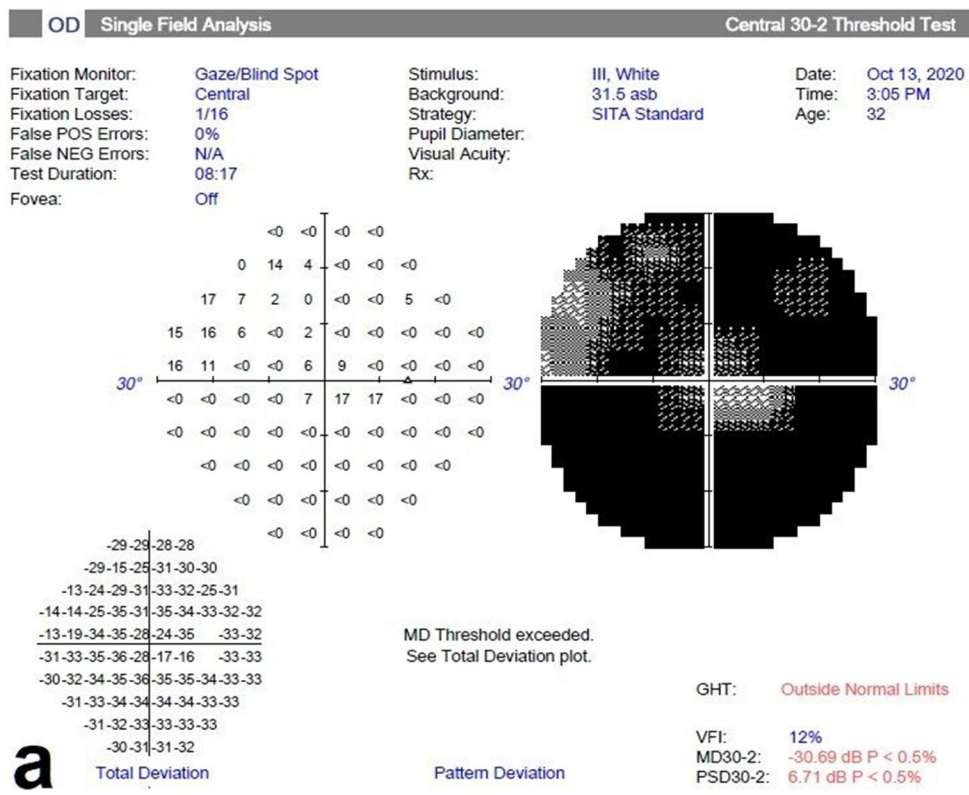


Fig. 4 30–2 visual field changes in the spheroidal MSC treatment (Table 1, Patient no. 9). **a** Before the treatment and **b** 6 months later after the treatment. Note the improvement in visual field

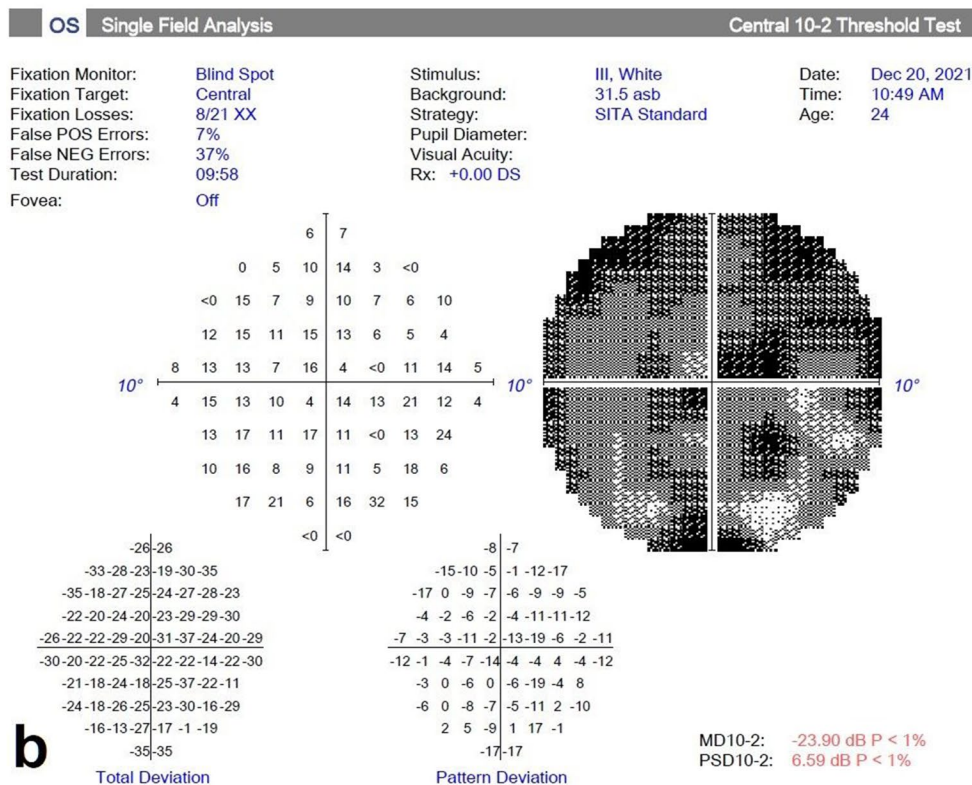
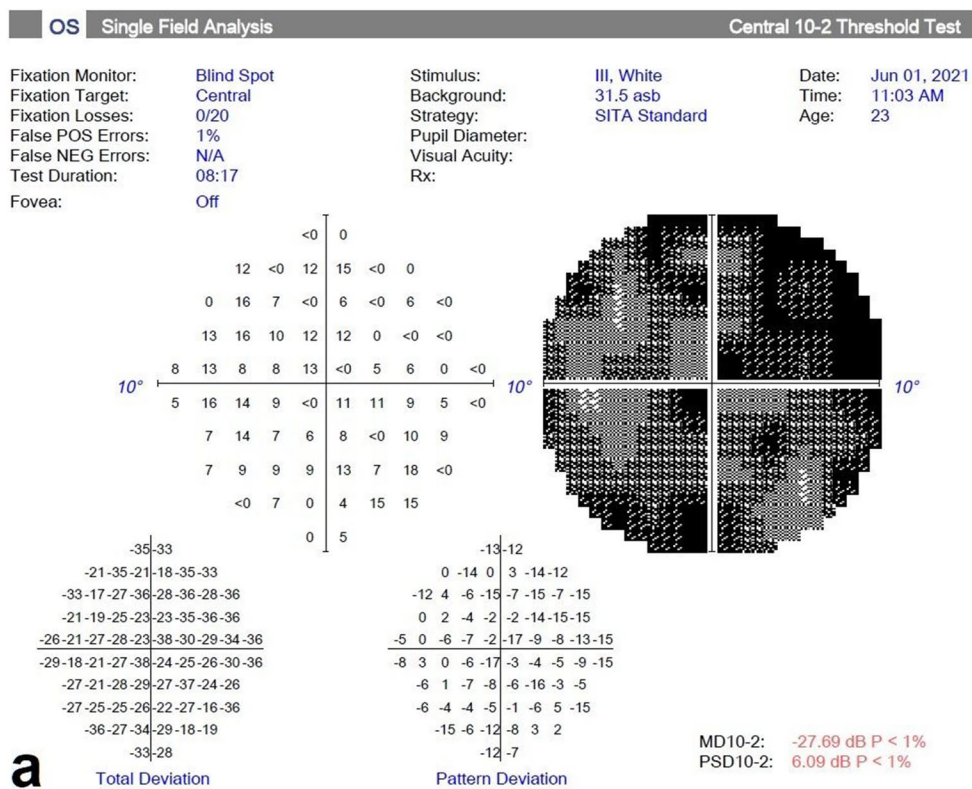


Fig. 5 10–2 visual field changes in the spheroidal MSC treatment (Table 1, Patient no. 3). **a** Before the treatment and **b** 6 months later after the treatment. Note the improvement in visual field

Table 3 Comparison of mfERG amplitudes of P1 waves at baseline and final examination (6th months) (*n* = 11)

	Ring	Amplitude of P1 wave (nV)		<i>p</i> *
		Preop	Postop. 6th months	
< 2°				
Treated eye	Median (IQR)	362.0 (159.0–612.0)	672.0 (564.0–1013.0)	0.014
	Mean ± SD	412.7 ± 291.7	830.3 ± 497.9	
Fellow eye	Median (IQR)	352.0 (163.0–600.0)	268.0 (225.0–564.0)	0.509
	Mean ± SD	399.1 ± 254.0	347.7 ± 174.9	
<i>p</i>		0.909**	0.001***	
2°–5°				
Treated eye	Median (IQR)	227.0 (180.0–297.0)	217.0 (167.0–446.0)	0.101
	Mean ± SD	215.2 ± 86.7	299.0 ± 174.2	
Fellow eye	Median (IQR)	180.0 (100.0–250.0)	200.0 (95.0–386.0)	0.406
	Mean ± SD	219.0 ± 175.0	255.3 ± 195.5	
<i>p</i>		0.365***	0.562***	
5°–10°				
Treated eye	Median (IQR)	163.0 (111.0–231.0)	282.0 (127.0–313.0)	0.018
	Mean ± SD	175.4 ± 86.4	248.3 ± 108.5	
Fellow eye	Median (IQR)	121.0 (75.0–131.0)	103.0 (94.0–198.0)	0.834
	Mean ± SD	129.0 ± 68.5	134.0 ± 75.2	
<i>p</i>		0.133***	0.009**	
10°–15°				
Treated eye	Median (IQR)	161.0 (92.2–170.0)	269.0 (174.0–295.0)	0.017
	Mean ± SD	147.4 ± 65.8	267.4 ± 139.5	
Fellow eye	Median (IQR)	164.0 (99.0–198.0)	120.0 (72.4–240.0)	0.883
	Mean ± SD	154.3 ± 62.0	149.6 ± 85.7	
<i>p</i>		0.802**	0.027**	
> 15°				
Treated eye	Median (IQR)	83.2 (53.1–183.0)	164.0 (91.0–210.0)	0.152
	Mean ± SD	117.2 ± 78.3	152.3 ± 69.5	
Fellow eye	Median (IQR)	77.4 (57.0–97.2)	100.0 (60.0–112.0)	0.053
	Mean ± SD	73.2 ± 26.1	98.3 ± 43.4	
<i>p</i>		0.102**	0.088***	

mfERG multifocal electroretinogram, *SD* standard deviation and *IQR* interquartile range

*Paired samples *t*-test

**Independent samples *t*-test

***Mann–Whitney *U*-test

Bold face values represent statistical significance

process by increasing the activity of the respiratory chain complex and ATP levels [36].

The previous studies showed the regenerative effect of mesenchymal stem cells in retinal diseases. Since studies using intravitreal injection or subretinal injection method for MSCs implantation resulted in side effects and complications [37, 38], sub-tenon or suprachoroidal route was recommended [3–6, 39, 40]. Özmert and Aslan have chosen the sub-tenon administration method for patients with RP. The eyes completing 1-year follow-up after the treatment showed significant improvement in visual acuity, visual field and ERG [6]. Limoli et al. [39] created a new technique for suprachoroidal implantation of stem cells. They created a scleral flap that they could see the reflex of the choroid in the flap’s bed. Then, they mobilized the fat pad near the inferior oblique muscle and placed it into this bed. After suturing the flap back, they injected the MSCs inside the fat pad. By this way, the investigators created a passage for the regenerative factors of the MSCs without placing them into the eye. First, they used this technique in patients with dry age-related macular degeneration. They followed the patients for 6 months, and they found that BCVA was improved, and microperimetry responses were increased in the treatment group. They also performed this technique in patients with RP [40]. The same technique was used in patients with RP and age-related macular degeneration by Kahraman et al. [3]. They evaluated BCVA, visual field and mfERG recordings of the patients with age-related macular degeneration, and they found improvements in these parameters at the 1st year of the follow-up. In patients with RP, they also found significant improvement in BCVA, visual field and mfERG recordings [4]. None of these studies report any complications or side effects with this treatment [3–6, 39, 40].

Limoli retinal restoration technique is a well-designed method for delivering mesenchymal stem cells. The adipose pedicle placed in the scleral bed maintains a safe and nutrient environment for the mesenchymal stem cells, additionally, being able to reintroduce PRP in the following period improve the efficacy of the method, and increases the duration of the mesenchymal secretome [39]. In our study, we used a matrix instead of a fat pedicle for two reasons. First, mesenchymal stem cells spheroids are too large to inject, they have to be placed. It is easier to place them in a solid bed. The second and more important reason is the characteristics of the extracellular matrix (ECM). It has been shown that when the stem cells are placed in phosphate-buffered saline (PBS), they

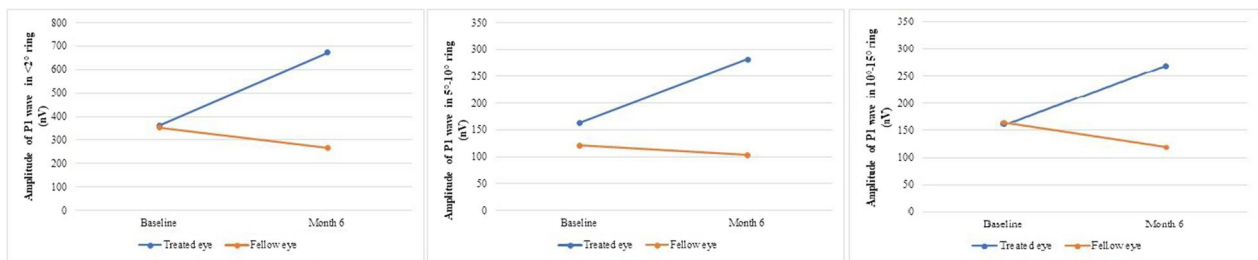


Fig. 6 Trends of the amplitudes of P1 waves in $<2^\circ$, $5^\circ-10^\circ$ and $10^\circ-15^\circ$ rings of treated and fellow eyes during the follow-up

Table 4 Comparison of mfERG implicit times of P1 waves at baseline and final examination (6th month) ($n = 11$)

	Ring	Implicit time of P1 wave (ms)		p^*
		Preop	Postop. 6th months	
$<2^\circ$				
Treated eye	Median (IQR)	51.9 (49.6–55.8)	41.4 (36.1–57.8)	0.163
	Mean \pm SD	51.4 \pm 9.34	44.8 \pm 11.6	
Fellow eye	Median (IQR)	52.9 (38.1–64.3)	43.7 (34.4–65.1)	0.754
	Mean \pm SD	51.3 \pm 14.4	49.5 \pm 16.6	
p		0.989**	0.0453**	
$2^\circ-5^\circ$				
Treated eye	Median (IQR)	53.6 (43.6–58.2)	43.1 (34.7–46.6)	0.073
	Mean \pm SD	51.1 \pm 10.3	43.9 \pm 9.5	
Fellow eye	Median (IQR)	42.2 (40.6–44.6)	44.3 (32.4–65.5)	0.645
	Mean \pm SD	44.1 \pm 8.9	46.1 \pm 15.9	
p		0.065***	0.700**	
$5^\circ-10^\circ$				
Treated eye	Median (IQR)	43.3 (37.9–61.3)	42.2 (32.3–54.6)	0.572
	Mean \pm SD	49.9 \pm 14.3	46.6 \pm 14.8 ^b	
Fellow eye	Median (IQR)	53.9 (42.2–69.0)	70.0 (47.7–72.3)	0.281
	Mean \pm SD	53.8 \pm 14.4	60.6 \pm 17.1	
p		0.531**	0.088***	
$10^\circ-15^\circ$				
Treated eye	Median (IQR)	65.2 (47.2–70.0)	49.6 (35.6–59.5)	0.004
	Mean \pm SD	59.2 \pm 13.6	47.2 \pm 12.2	
Fellow eye	Median (IQR)	47.2 (64.3–67.7)	60.0 (40.4–67.9)	0.120
	Mean \pm SD	50.5 \pm 16.4	57.7 \pm 14.9	
p		0.192**	0.087**	
$>15^\circ$				
Treated eye	Median (IQR)	52.3 (53.1–183.0)	57.3 (43.2–67.5)	0.515
	Mean \pm SD	51.0 \pm 10.3	54.6 \pm 13.2	
Fellow eye	Median (IQR)	52.3 (40.8–63.2)	53.6 (40.0–65.0)	0.952
	Mean \pm SD	53.4 \pm 11.3	53.1 \pm 16.6	
p		0.605**	0.819**	

mfERG multifocal electroretinogram, *SD* standard deviation and *IQR* interquartile range

*Paired samples *t*-test

**Independent samples *t*-test

***Mann–Whitney *U*-test

Bold face value represents statistically significant improvement in implicit time of P1 waves in $10^\circ-15^\circ$ rings postoperatively

lose their correct cell/ECM connections. This results in a form of apoptosis, termed anoikis [41]. ECM provides a scaffold for the stem cells increasing their viability. It has been reported that encapsulating stem cells in an ECM creates a pro-regenerative environment, and paracrine effects of the stem cells could be optimized [42]. Additionally, ECM may deliver numerous soluble and immobilized factors that could elevate the therapeutic effects of the stem cells [43].

MSC preparation as spheroids has been shown to have improved anti-inflammatory, regenerative and reparative effects [41–45]. When MSCs form spheroids, they create a microenvironment that improves their survival. In an animal study, it has been demonstrated that spheroidal stem cells remained for 14 days in the tissues. On the other hand, the persistence of suspension MSC injections is limited to 7 days in same study [46]. The microenvironment upregulates the potential of each MSC and strengthens its secretion. As a result, paracrine secretion of angiogenic, antitumorigenic, anti-inflammatory and immunomodulatory is enhanced, differentiation potentials are increased and replicative senescence is delayed in this microenvironment [47]. The previous studies demonstrated the regenerative effect of spheroidal MSCs in cardiomyocytes, neural cells, cartilage and wound healing [4, 48–50]. In the light of these findings, it could be possible to propose that the improved spheroidal MSCs may also be more effective in regenerating and protecting the retinal cells. In line with that idea, our study demonstrated a significant improvement in visual acuity and visual fields of the patients with RP with spheroidal MSCs. To the best of our knowledge, the present study is the first to use spheroidal MSCs in the treatment of RP. Further studies that would show the duration of these effects should be conducted. Methods for re-implantation or PRP re-injection (like in LRRT) should also be investigated.

In phase III clinical trial of suprachoroidal implantation of umbilical cord-derived MSC in RP, suprachoroidal implantation, which we modified using spheroids as described above, Kahraman and Öner [4] reported visual

acuity improvement in 46% of the patients ($p < 0.05$), stabilization in 42% and worsening in 12% in 6 months follow-up period. However, our results demonstrated visual acuity improvement in 80% of the patients ($p < 0.001$) and stabilization in 20% of the patients. None of our patients had worsening in visual acuity during the follow-up period. Similar to our study, they also showed significant improvement in 30/2 visual field testing of the patients. Moreover, 10/2 visual field testing showed significant improvement in the current study. mfERG tests in Kahraman and Öner study [4] revealed statistically significant improvement in P1 amplitudes in the central rings ($< 2^\circ$ and $2^\circ\text{--}5^\circ$) and a slight decrease in the peripheral rings. The current study conducted with patients with relatively good visual acuity revealed improvement in P1 amplitudes in all mfERG rings, but the improvements in $< 2^\circ$, $5^\circ\text{--}10^\circ$ and $10^\circ\text{--}15^\circ$ rings were statistically significant. These findings are in line with Limoli et al. study conducted on RP patients which found that patients with foveal thickness > 190 microns had markedly good BCVA [40]. Additionally, further studies that compare the effects of spheroidal MSCs with sub-tenon or suprachoroidal injection of non-spheroidal MSCs should be carried out.

The small sample size and short duration of follow-up can be considered limitations of our study. The second limitation was that there was not any study in the literature using spheroidal MSCs in the treatment of RP, and thus, the results of our study could not be supported and compared. Additionally, the genetic mutation analyses of the patients were variable, and we could not make a comment related with genetic factor and treatment response. Further studies with a larger sample size and longer follow-up can be performed to support our findings.

Conclusion

RP is characterized by progressive loss of photoreceptors and consequently loss of visual acuity. Current treatment modalities are not able to treat the disease. Our results provide clear evidence that MSCs are shown to have regenerative effects in patients with RP. Moreover, this is the first study to show visual improvement with mesenchymal stem cell application in RP patients with relatively good visual acuity. Spheroidal MSCs with enhanced effects may be more successful in preventing apoptosis and improving cellular restoration.

Abbreviations

RP	Retinitis pigmentosa
RPE	Retinal pigment epithelium
MSC	Mesenchymal stem cell
BCVA	Best-corrected visual acuity
MD	Mean deviation
PSD	Pattern standard deviation

VF	Visual field
ISCEV	International Society for Clinical Electrophysiology of Vision
logMAR	Logarithm of the minimal angle of resolution
mfERG	Multifocal electroretinography
PRP	Platelet-rich plasma
MSAs	Mean signal amplitudes
ECM	Extracellular matrix
PBS	Phosphate-buffered saline

Acknowledgements

None.

Author contributions

BÖ and EO helped in conceptualization; BÖ and EO helped in methodology; BÖ, CH, GSK and ÖŞ helped in formal analysis and investigation; BÖ and BYT contributed to writing—original draft preparation; BÖ and BYT contributed to writing—review and editing; funding acquisition: none; resources: none and BÖ and EO worked in supervision. All authors commented on previous versions of the manuscript. All authors read and approved the final manuscript.

Funding

No funding was received for conducting this study.

Availability of data and materials

Data available on request.

Declarations

Ethics approval and consent to participate

All procedures performed in studies involving human participants were in accordance with the ethical standards of the institutional and/or national research committee and with the 1964 Helsinki Declaration and its later amendments or comparable ethical standards. The study entitled "Implantation of Spheroids Containing Stem Cells in the Suprachoroidal Area" was approved by the ethics committee of Review Board of Cell, Organ and Tissue Transplantation Department of Turkish Ministry of Health (Date: 30.07.2019, No: 56733164/203 E.3858).

Informed consent

Informed consent was obtained from all individual participants included in the study.

Consent for publication

Consent for publication has been obtained from all individual participants included in the study.

Competing interest

The authors have no conflicts of interest to declare that are relevant to the content of this article.

Received: 27 November 2022 Accepted: 4 September 2023

Published online: 13 September 2023

References

1. Wright AF, Chakarova CF, Abd El-Aziz MM, Bhattacharya SS. Photoreceptor degeneration: genetic and mechanistic dissection of a complex trait. *Nat Rev Genet.* 2010;11:273–84.
2. McLaughlin ME, Sandberg MA, Berson EL, Dryja TP. Recessive mutations in the gene encoding the beta-subunit of rod phosphodiesterase in patients with retinitis pigmentosa. *Nat Genet.* 1993;4:130–4.
3. Kahraman NS, Gonen ZB, Sevim DG, Öner A. First year results of suprachoroidal adipose tissue derived mesenchymal stem cell implantation in degenerative macular diseases. *Int J Stem Cells.* 2021;14:47–57.
4. Kahraman NS, Öner A. Umbilical cord derived mesenchymal stem cell implantation in retinitis pigmentosa: a 6-month follow-up results of a phase 3 trial. *Int J Ophthalmol.* 2020;13:1423–9.

5. Özmert E, Arslan U. Management of retinitis pigmentosa by Wharton's jelly derived mesenchymal stem cells: preliminary clinical results. *Stem Cell Res Ther.* 2020;11:25.
6. Özmert E, Arslan U. Management of retinitis pigmentosa by Wharton's jelly-derived mesenchymal stem cells: prospective analysis of 1-year results. *Stem Cell Res Ther.* 2020;11:353.
7. Oner A, Gonen ZB, Sevim DG, et al. First-year results of subretinal mesenchymal stem cell implantation in severe retinitis pigmentosa. *J Stem Cell Res Ther.* 2019;9:454.
8. Sharma R, Bose D, Maminishkis A, Bharti K. Retinal pigment epithelium replacement therapy for age-related macular degeneration: are we there yet? *Annu Rev Pharmacol Toxicol.* 2020;60:553–72.
9. Zarbin M. Cell-based therapy for degenerative retinal disease. *Trends Mol Med.* 2016;22:115–34.
10. Aladdad AM, Kador KE. Adult stem cells, tools for repairing the retina. *Curr Ophthalmol Rep.* 2019;7:21–9.
11. Lund RD, Wang S, Lu B. Cells isolated from umbilical cord tissue rescue photoreceptors and visual functions in a rodent model of retinal disease. *Stem Cells.* 2007;25:602–11.
12. Wysocka AM, Kot M, Sułkowski M, et al. Molecular and functional verification of Wharton's jelly Mesenchymal stem cells (WJ-MSCs) pluripotency. *Int J Mol Sci.* 2019;20:1807.
13. Rivero JEM, Nicolás FMN, Bernal DG, et al. Human Wharton's jelly mesenchymal stem cells protect axotomized rat retinal ganglion cells via secretion of antiinflammatory and neurotrophic factors. *Sci Rep.* 2018;8:16299.
14. Leow SN, Luu CD, Hairul Nizam MH, et al. Safety and efficacy of human Wharton's jelly-derived mesenchymal stem cells therapy for retinal degeneration. *PLoS ONE.* 2015;10:e0128973.
15. Ruiz FL, Romero CG, Bernal GD, et al. Mesenchymal stromal cell therapy for damaged retinal ganglion cells, is gold all that glitters? *Neural Regen Res.* 2019;14:1851–7.
16. Ji S, Lin S, Chen J, et al. Neuroprotection of transplanting human umbilical cord mesenchymal stem cells in a microbead induced ocular hypertension rat model. *Curr Eye Res.* 2018;43:810–20.
17. Choi SW, Kim JJ, Seo MS, et al. Inhibition by miR-410 facilitates direct retinal pigment epithelium differentiation of umbilical cord blood-derived mesenchymal stem cells. *J Vet Sci.* 2017;18:59–65.
18. Wu M, Zhang R, Zou Q, et al. Comparison of the biological characteristics of Mesenchymal stem cells derived from the human placenta and umbilical cord. *Sci Rep.* 2018;8:5014.
19. Karahuseynoglu S, Çınar Ö, Kılıç E, et al. Biology of stem cells in human umbilical cord Stroma: in situ and in vitro surveys. *Stem Cells.* 2007;25:319–31.
20. Koenekoop RK. Why some photoreceptors die, while others remain dormant: lessons from RPE65 and LRAT associated retinal dystrophies. *Ophthalmic Genet.* 2011;32:126–8.
21. Wang W, Lee SJ, Scott PA, et al. Two-step reactivation of dormant cones in retinitis pigmentosa. *Cell Rep.* 2016;15:372–85.
22. Wong F, Kwok SY. The survival of cone photoreceptors in retinitis pigmentosa. *JAMA Ophthalmol.* 2016;134(249–250):11.
23. Sahel JA, Leveillard T, Picaud S, Dalkara D, Marazova K, et al. Functional rescue of cone photoreceptors in retinitis pigmentosa. *Graefes Arch Clin Exp Ophthalmol.* 2013;251:1669–77.
24. Daftarian N, Kiani S, Zahabi A. Regenerative therapy for retinal disorders. *J Ophthalmic Vis Res.* 2010;5:250–64.
25. Park SS. Cell therapy applications for retinal vascular diseases: diabetic retinopathy and retinal vein occlusion. *Invest Ophthalmol Vis Sci.* 2016;57:ORSFj1–10.
26. Zhang W, Wang Y, Kong J, et al. Therapeutic efficacy of neural stem cells originating from umbilical cord-derived mesenchymal stem cells in diabetic retinopathy. *Sci Rep.* 2017;7:408.
27. Hood DC, Bach M, Brigell M, et al. ISCEV standard for clinical multifocal electroretinography (mfERG) (2011 edition). *Doc Ophthalmol.* 2012;124:1–13.
28. Hollingsworth TJ, Gross AK. Defective trafficking of rhodopsin and its role in retinal degenerations. *Int Rev Cell Mol Biol.* 2012;293:1–44.
29. Bowne SJ, Sullivan LS, Blanton SH, Cepko CL, Blackshaw S, Birch DG, Hughbanks-Wheaton D, Heckenlively JR, Daiger SP. Mutations in the inosine monophosphate dehydrogenase 1 gene (IMPDH1) cause the RP10 form of autosomal dominant retinitis pigmentosa. *Hum Mol Genet.* 2002;11:559–68.
30. Newton F, Megaw R. Mechanisms of photoreceptor death in retinitis pigmentosa. *Genes (Basel).* 2020;11:1120.
31. Campochiaro PA, Strauss RW, Lu L, et al. Is there excess oxidative stress and damage in eyes of patients with retinitis pigmentosa? *Antioxid Redox Signal.* 2015;23:643–8.
32. Lieberthal W, Triaca V, Koh JS, et al. Role of superoxide in apoptosis induced by growth factor withdrawal. *Am J Physiol.* 1998;275(5):F691–702.
33. Drago D, Cossetti C, Iraci N, et al. The stem cell secretome and its role in brain repair. *Biochimie.* 2013;95:2271–85.
34. Hu ZL, Li N, Wei X, et al. Neuroprotective effects of BDNF and GDNF in intravitreally transplanted mesenchymal stem cells after optic nerve crush in mice. *Int J Ophthalmol.* 2017;10:35–42.
35. Lai RC, Yeo RW, Lim SK. Mesenchymal stem cell exosomes. *Semin Cell Dev Biol.* 2015;40:82–8.
36. Islam MN, Das SR, Emin MT, et al. Mitochondrial transfer from bone-marrow-derived stromal cells to pulmonary alveoli protects against acute lung injury. *Nat Med.* 2012;18:759–65.
37. Tassoni A, Gutteridge A, Barber AC, et al. Molecular mechanisms mediating retinal reactive gliosis following bone marrow mesenchymal stem cell transplantation. *Stem Cells.* 2015;33:3006–16.
38. Satarian L, Nourinia R, Safi S, et al. Intravitreal injection of bone marrow mesenchymal stem cells in patients with advanced retinitis pigmentosa; a safety study. *J Ophthalmic Vis Res.* 2017;12:58–64.
39. Limoli PG, Vingolo EM, Limoli C, et al. Regenerative therapy by suprachoroidal cell autograft in dry age-related macular degeneration: preliminary in vivo report. *J Vis Exp.* 2018;132:56469.
40. Limoli PG, Limoli CSS, Marco Morales MU, Vingolo EM. Mesenchymal stem cell surgery, rescue and regeneration in retinitis pigmentosa: clinical and rehabilitative prognostic aspects. *Restor Neurol Neurosci.* 2020;38:223–37.
41. Bartosh TJ, Ylo's talo JH, Mohammadipoor A, et al. Aggregation of human mesenchymal stromal cells (MSCs) into 3D spheroids enhances their anti-inflammatory properties. *Proc Natl Acad Sci U S A.* 2010;107:13724–9.
42. Kim J, Ma T. Endogenous extracellular matrices enhance human mesenchymal stem cell aggregate formation and survival. *Biotechnol Prog.* 2013;29:441–51.
43. Lee EJ, Park SJ, Kang SK, et al. Spherical bullet formation via E-cadherin promotes therapeutic potency of mesenchymal stem cells derived from human umbilical cord blood for myocardial infarction. *Mol Ther.* 2012;20:1424–33.
44. Bhang SH, Lee S, Shin JY, et al. Transplantation of cord blood mesenchymal stem cells as spheroids enhances vascularization. *Tissue Eng Part A.* 2012;18:2138–47.
45. Rettinger CL, Fourcaudot AB, Hong SJ, et al. In vitro characterization of scaffold-free three-dimensional mesenchymal stem cell aggregates. *Cell Tissue Res.* 2014;358:395–405.
46. Hsu TW, Lu YJ, Lin YJ, et al. Transplantation of 3D MSC/HUVEC spheroids with neuroprotective and proangiogenic potentials ameliorates ischemic stroke brain injury. *Biomaterials.* 2021;272:12765.
47. Cesarz Z, Tamama K. Spheroid culture of mesenchymal stem cells. *Stem Cells Int.* 2016;2016:9176357.
48. He J, Zhang N, Zhu Y, et al. MSC spheroids-loaded collagen hydrogels simultaneously promote neuronal differentiation and suppress inflammatory reaction through PI3K-Akt signaling pathway. *Biomaterials.* 2021;265:120448.
49. Murphy KC, Whitehead J, Zhou D, et al. Engineering fibrin hydrogels to promote the wound healing potential of mesenchymal stem cell spheroids. *Acta Biomater.* 2017;64:176–86.
50. Ko JY, Park JW, Kim J, Im GI. Characterization of adipose-derived stromal/stem cell spheroids versus single-cell suspension in cell survival and arrest of osteoarthritis progression. *J Biomed Mater Res A.* 2021;109:869–78.

Publisher's Note

Springer Nature remains neutral with regard to jurisdictional claims in published maps and institutional affiliations.